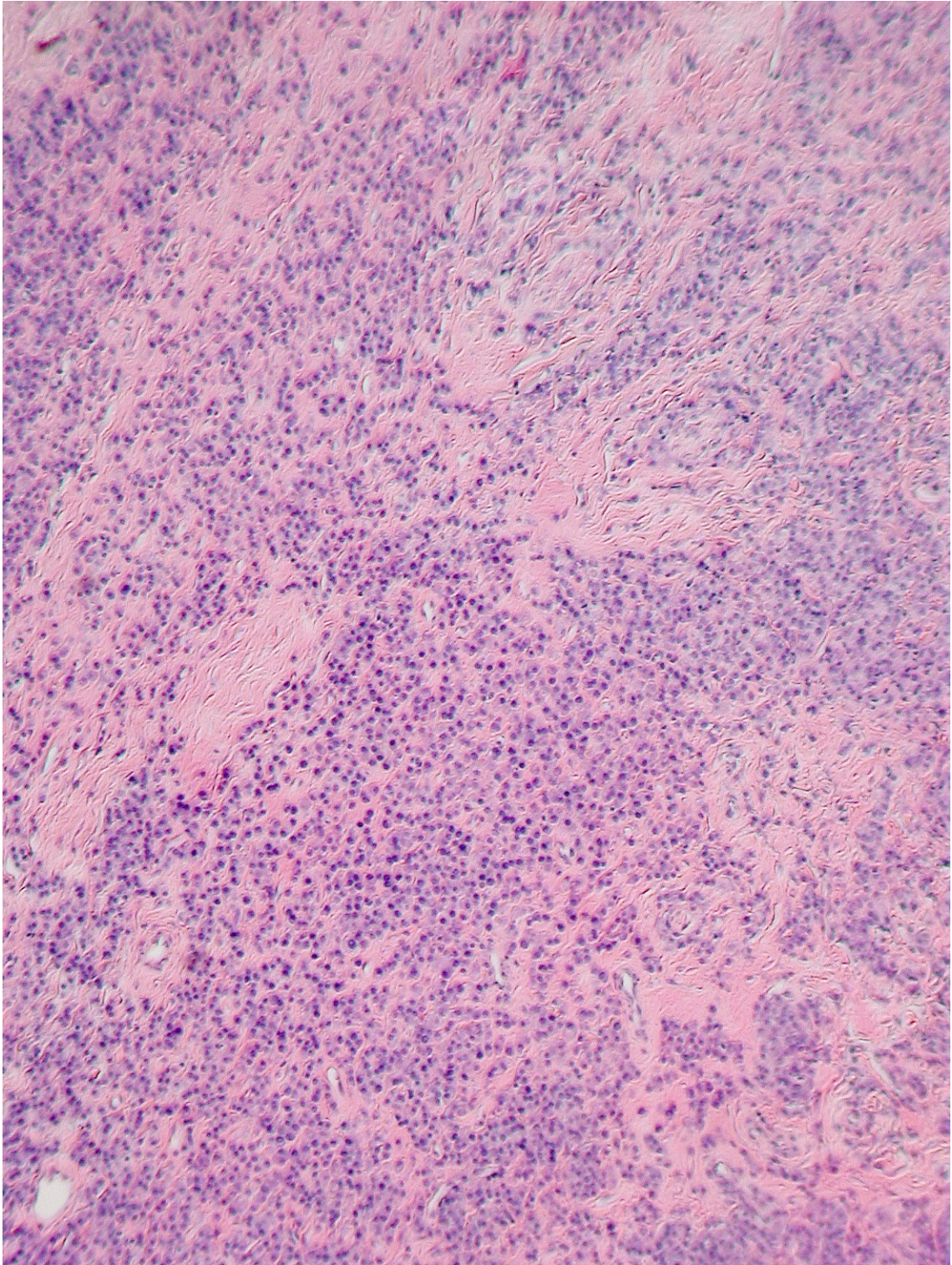


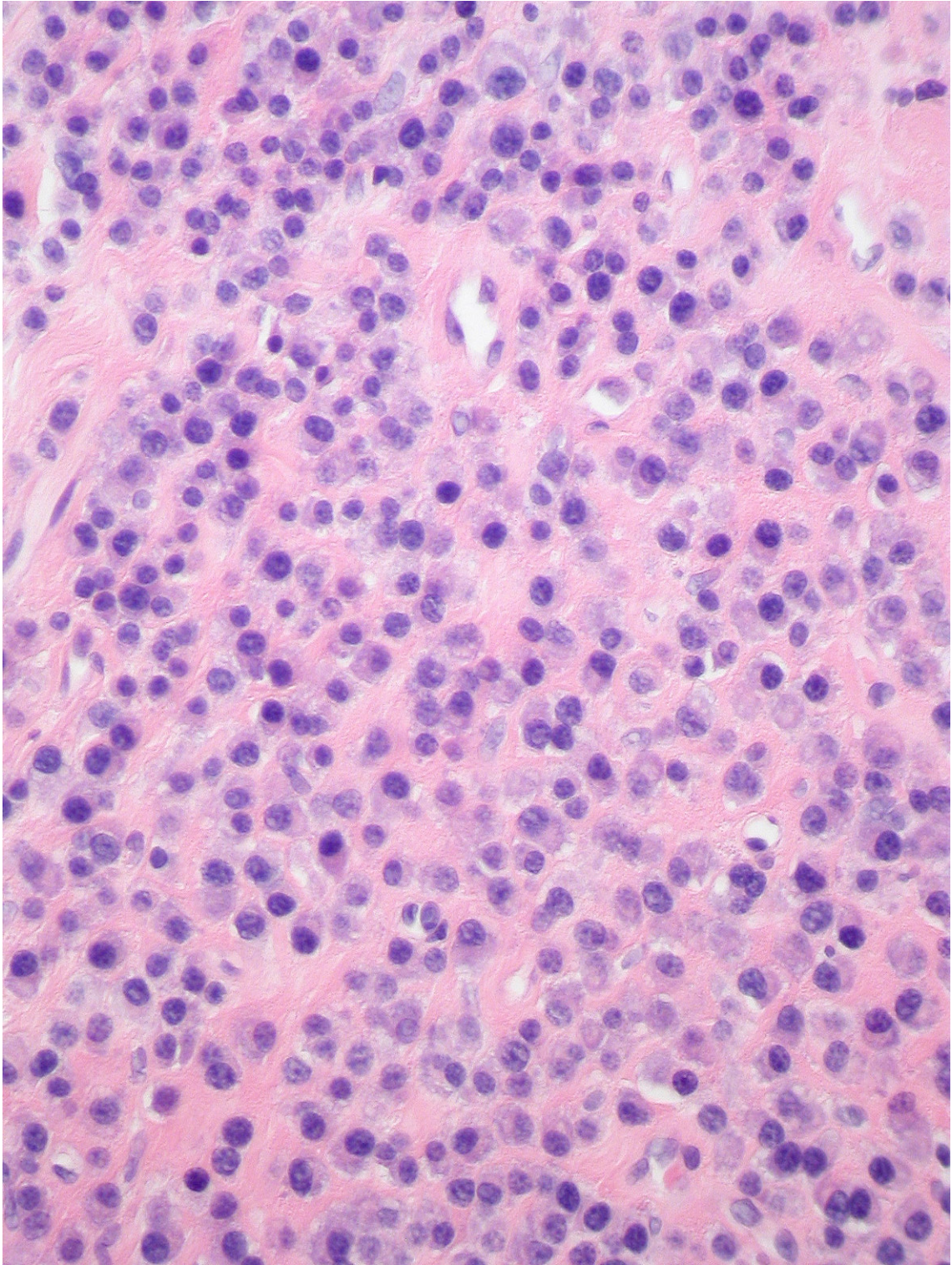
Slide Seminar

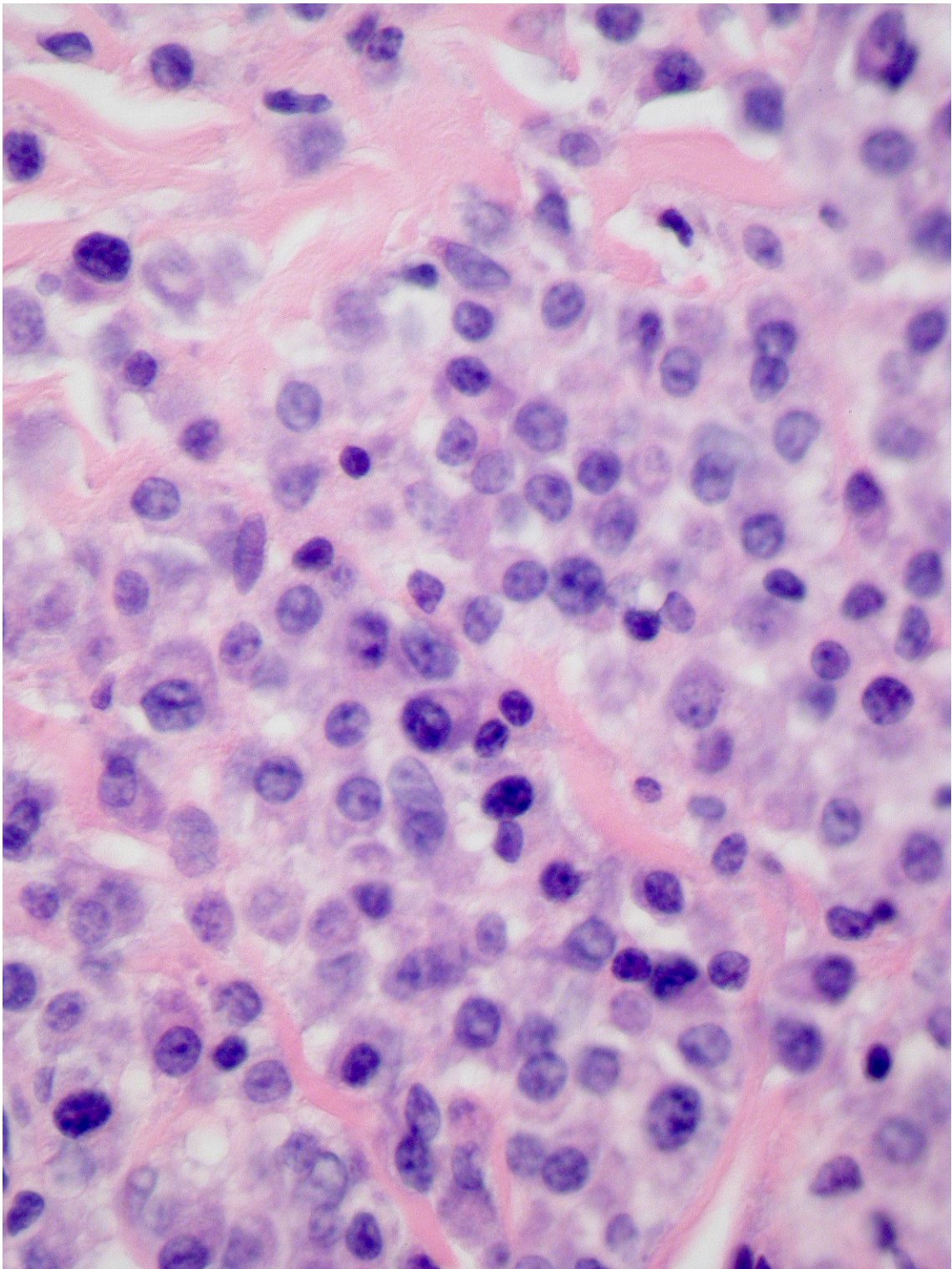
Oral Pathology

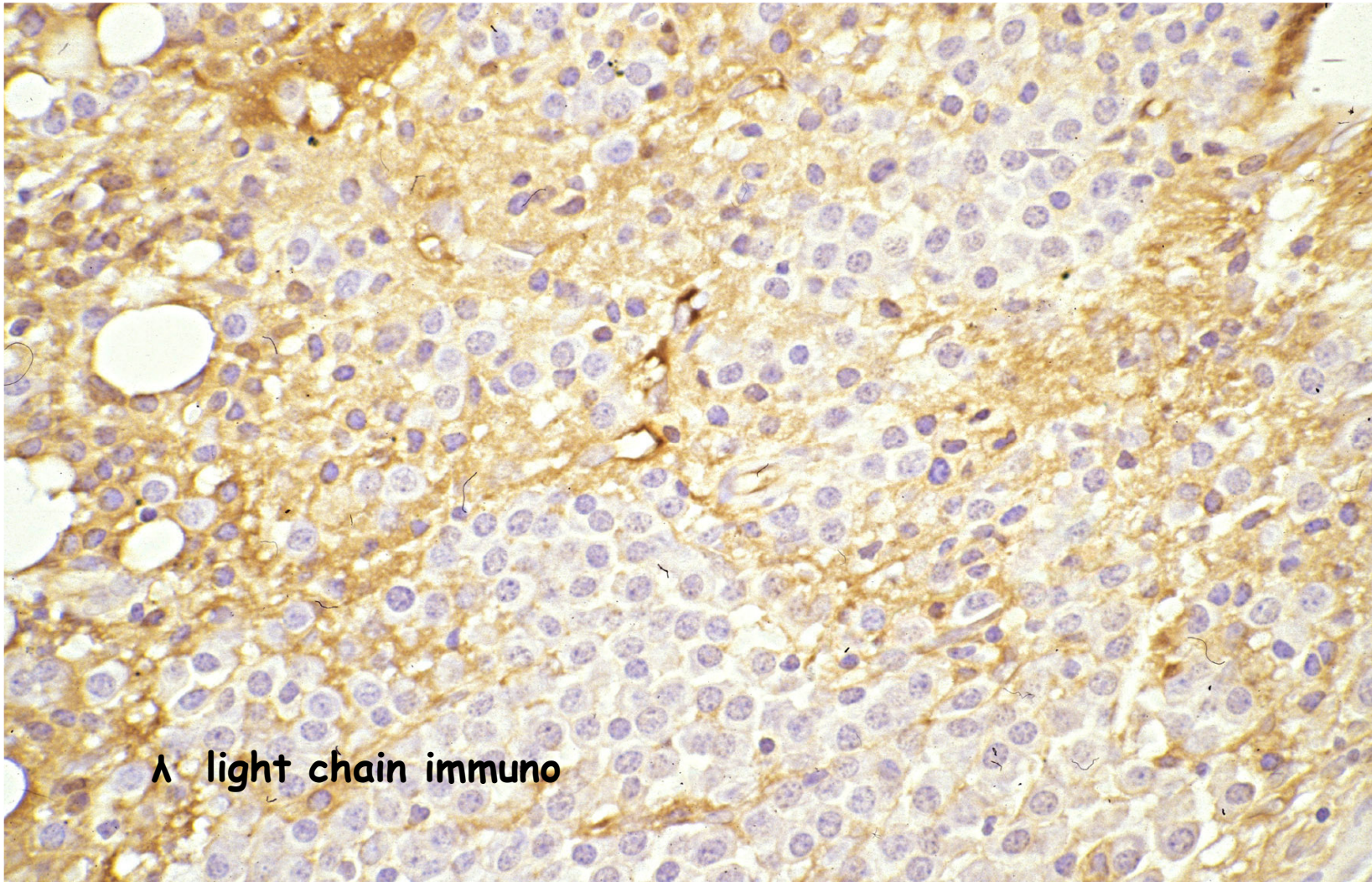
Male 72y

8month history of slow growing swelling
left palate mucosa/alveolar ridge lower 3-
6 region; painless, rubbery to feel and
does not bleed.

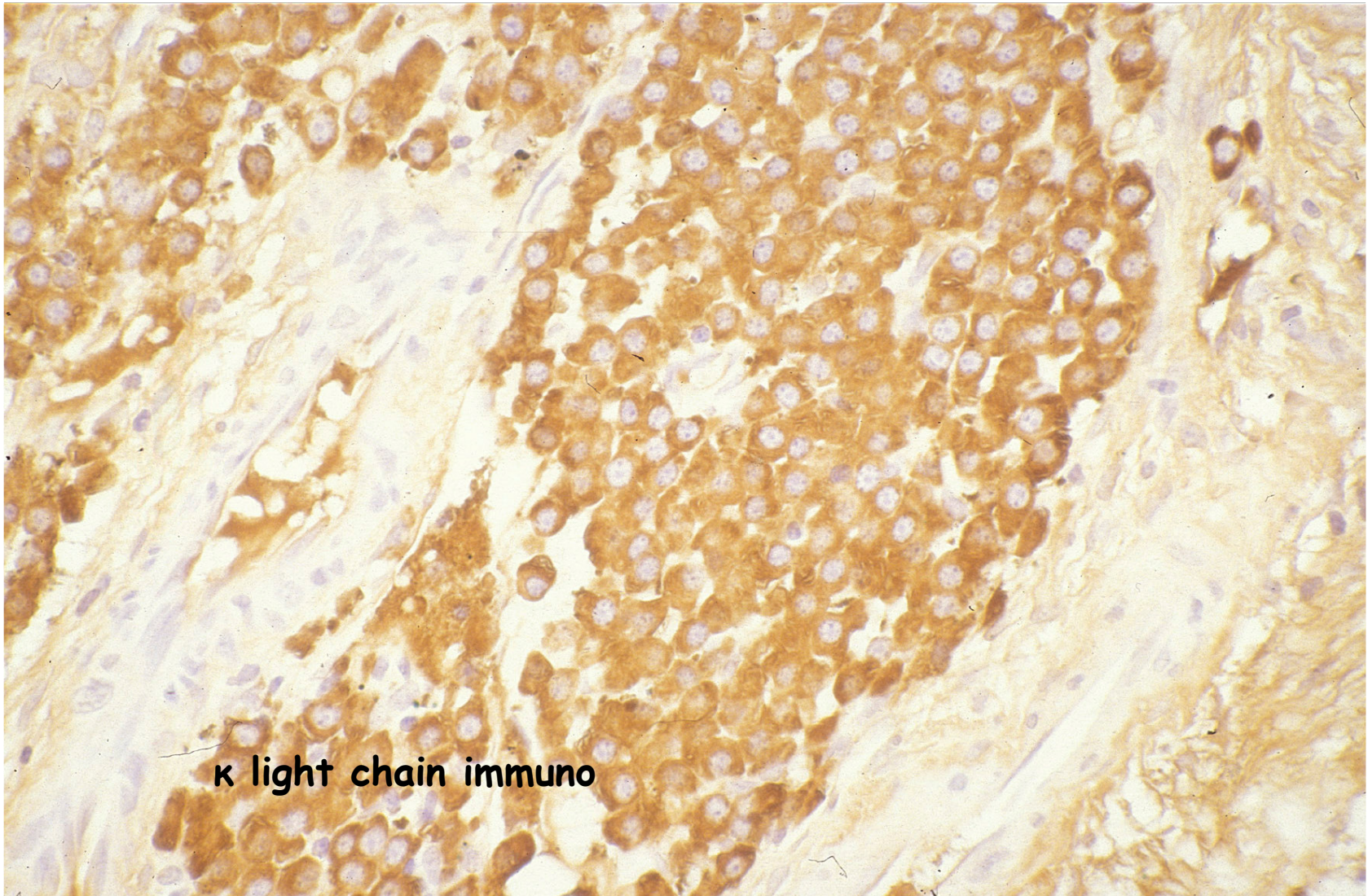








λ light chain immuno



κ light chain immuno